

Morphometric Study Of Sutural Bones Of Orbit With Their Clinical Implications

Reeha Mahajan¹, Anita Tuli¹, Shashi Raheja¹, Shaili Tomer², Sarita Beri³

¹Department of Anatomy, B.J. G Medical College & Sassoon Hospital, Pune, India

²Department of Radiology, Lady Hardinge Medical College & Associated Hospitals, New Delhi, India

³Department of Ophthalmology, Lady Hardinge Medical College & Associated Hospitals, New Delhi, India

How to cite this paper: Mahajan, R. et al. (2018) Morphometric Study Of Sutural Bones Of Orbit With Their Clinical Implications. *International Journal of Clinical and Experimental Medicine Research*, 2(2), 29-36. DOI: 10.26855/ijcemr.2018.02.001

Corresponding to: Dr. Reeha Mahajan, B.J. G Medical College & Sassoon Hospital, Pune, India
E-mail: mahajan.reeha@gmail.com

Abstract

The sutural bones form an integral part of orbit occupying the sutural gaps. The awareness of their presence is of paramount importance while performing orbital surgery and imaging procedures. This study is an attempt to find the frequency of occurrence of sutural bones in the walls of orbit and the neighboring facial skeleton with explanation of their morphology as well as surgical importance. The study was conducted on 320 dry adult skulls of North Indian origin obtained from the department of Anatomy, Lady Hardinge Medical College, New Delhi. The skulls were observed for the presence of sutural bones in the four walls of orbit and facial skeleton bilaterally which were confirmed radiologically on computerized tomography. The sizes of these bones were measured and the mean as well as standard deviations of the values were calculated. Sutural bones were seen in the orbit and facial skeleton in 102 (31.9%) skulls, with the lateral wall, medial wall, floor, roof and the facial skeleton presenting with 40(12.5%), 12(3.75%), 8(2.5%), 12(3.75%) and 30(9.4%) bones respectively varying in their number, size, shape and location. The organization and perplexing relations of neurovascular structures in this region makes it imperative, that the surgeons be knowledgeable about these morphologic variants.

Keywords

Sutural bone, Orbit, Computerized Tomography, Embryology, Fractures

Introduction

A comprehensive study of the anatomy and morphological boundaries of the orbit is of clinical interest to ophthalmologists, otorhinolaryngologists, neurosurgeons, oral and maxillofacial surgeons. Orbitotomy, a surgical procedure done to obtain access to a particular area of the orbit through its walls, is performed for multiple reasons, including biopsy or excision of lesions in the orbit, draining an abscess, removing a foreign body, bone or fat for decompression of the orbit and for orbital fracture repair. The surgical interventions and instrumentation near the small sutural bones may traumatize important neural and vascular structures. The awareness of their presence in the orbit is of paramount importance while performing orbital surgery and imaging procedures for the treatment of its congenital deformities and fractures. A meticulous preoperative evaluation of orbit by imaging techniques is necessary for patients undergoing maxillofacial surgery. Their identification will help in distinguishing sutural lines from fractures. This study is an attempt to find the frequency of occurrence of sutural bones in the walls of the orbit and neighboring facial skeleton with explanation of their morphology as well as surgical importance.

MATERIALS AND METHODS

The present study is an observational study conducted, after approval from institution review board, on 320 dry adult skulls (n=320) belonging to the Aryo-Dravidian racial type of North Indian origin obtained from the department of Anatomy, Lady Hardinge Medical College, New Delhi, of which, 220 skulls belonged to males and 100 to females. All the samples were obtained and used for research after written informed consent from the donor or the next of kin. The mean cranial and facial indices for the two sexes were 80.2, 79.1 and 53.5, 52.3 respectively (Williams *et al.*, 1995). All skulls with deformities and any history of trauma and metabolic disorders were excluded from the study. All skulls were looked for the presence of sutural bones using a magnifying glass. The number, exact location, size and shape of sutural bones were noted in all the four walls of orbit (roof, floor, medial and lateral walls) and facial skeleton on both the sides. The sizes of these bones were measured by taking their maximum diameters perpendicular to each other with the help of digital Vernier caliper (Biomed Healthcare Pvt. Ltd., Mumbai, India), double blindly, by two authors. The mean and standard deviations of the above values were calculated. The presence of sutural bones on the skulls was correlated with the radiographic (CT images) of the same, obtained on the CT scanner (Philips Brilliance 40).

Results

Sutural bones were observed in all the four walls of the orbit and on the facial skeleton. Out of the 320 skulls observed in the study, 102 (31.9%) skulls exhibited sutural bones which varied in their number, size, shape and location. The total number of orbital and facial bones were 72 (22.5%) and 30(9.4%) respectively. The mean dimensions of the sutural bones have been summarized in table1.

Sutural bones in the lateral wall of the orbit

They were observed in 40(12.5%) skulls and were present in equal numbers, both bilaterally and unilaterally (6.25% each). These bones were observed at 4 locii viz:

Locus 1: In eight skulls (2.5%), SB was observed on the right side, unilaterally at frontozygomatic suture (Fig. 1).

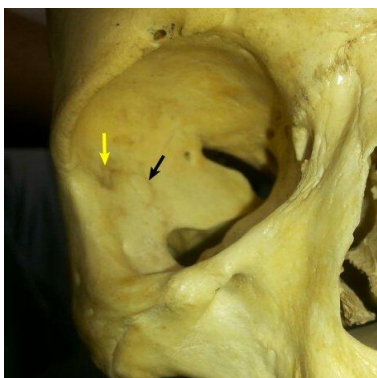


Fig.1 Sutural bones at the frontozygomatic suture (yellow arrow) and sphenofrontozygomatic suture in the lateral wall of the right orbit (black arrow)

Locus 2: In sixteen skulls (5%), SB was observed at the sphenozygomatic suture, being bilateral in twelve (3.75%) skulls. Fig. 2 shows the SB at the sphenozygomatic suture.

Locus 3: In four skulls (1.25%), one sutural bone was wedged at the frontosphenoidal unilaterally on the right side (Fig. 3).

Locus 4: In twelve skulls (3.75%), one sutural ossicle was observed at the sphenofrontozygomatic suture, bilaterally in eight(2.5%) skulls and unilaterally in four (1.25%) skulls with two each on the right and left side (Fig. 1, 4a, 4b, 4c). The CT image shown in fig. 4b is a reconstructed, shaded surface volume rendering image of CT scan of skull showing SB at

the junction of greater wing of sphenoid, zygomatic process of frontal bone and zygomatic bone which is better visualized in zoomed image.

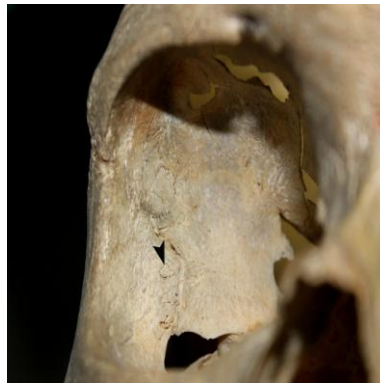

Fig. 2 Sutural bone at the sphenozygomatic suture (arrowhead) in the lateral wall of right orbit

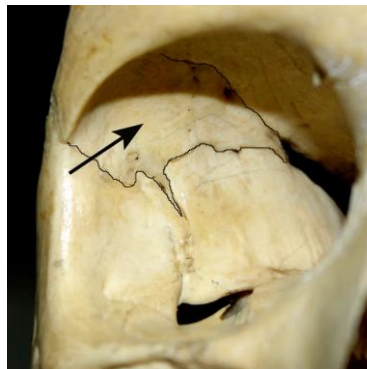


Fig. 3 Sutural bone at the frontosphenoidal suture in the lateral wall of right orbit(arrow)

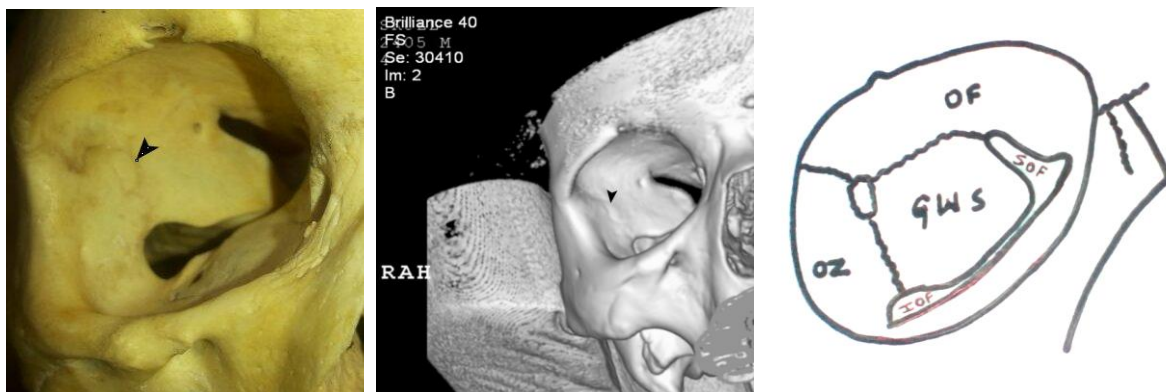


Fig. 4 a. Sutural bone at the sphenofrontozygomatic suture in the lateral wall of right orbit(arrowhead), **b.** Shaded surface volume rendering image of CT scan of skull showing sutural bone at the sphenofrontozygomatic suture in the lateral wall of right orbit(arrowhead), **c.** Schematic diagram showing sutural bone at the junction of orbital part of frontal bone(OF), orbital surface of greater wing of sphenoid(GWS) and orbital surface of zygomatic bone(OZ) in the lateral wall of right orbit

Sutural bones in the medial wall of the orbit

Locus 5: Frontoethmoidal suture- In twelve skulls (3.75%), SB was seen at the junction of orbital part of frontal bone and orbital plate of ethmoid bone unilaterally. (Fig. 5a, 5b)

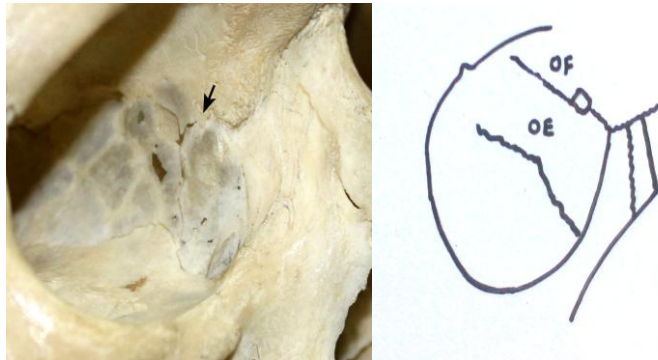

Fig. 5 a. Sutural bone at the frontoethmoidal suture in the medial wall of right orbit(arrow), **b.** Schematic diagram showing sutural bone at the junction of orbital plate of ethmoid(OE) & orbital part of frontal bone(OF) in the medial wall of right orbit

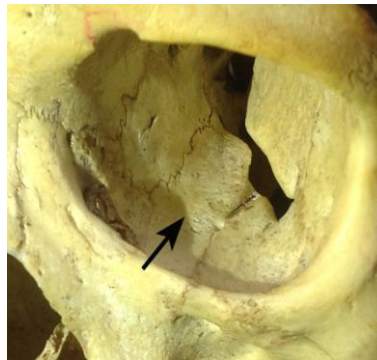


Fig. 6 Sutural bone at the ethmoidomaxillary suture in the floor of left orbit (arrow)

Sutural bones in the floor of the orbit

Locus 6: Ethmoidomaxillary suture- In eight (2.5%) skulls, SB was seen at the junction of orbital plate of ethmoid and orbital surface of maxilla unilaterally. It was seen on the right side in six (1.9%) and on the left side in two (0.6%) skulls (Fig. 6).

Sutural bones in the roof of the orbit

They were observed in 12(3.75%) skulls at the following locii:

Locus 7: In eight skulls (2.5%), SB was seen in the orbital plate of frontal bone one-sidedly. It was seen on the right side in five (1.6%) skulls and on the left side in three (0.9%) skulls

Locus 8: In four skulls (1.25%), one suturalbone was seen at the junction of lesser wing of sphenoid and orbital plate of frontal bone unilaterally, on the right side in one (0.3%) skull (Fig.7).

Sutural bones in the facial skeleton

They were observed in 30(9.4%) skulls at the following locii: Locus 9: In two skulls (0.6%), they were seen at the frontolacrimal suture unilaterally on the right side (Fig. 8).

Locus 10: In four skulls (1.25%), SB was wedged at the maxillozygomaticolacrimal suture unilaterally. It was seen on the right side in three (1.6%) skulls.

Locus 11: In four skulls (1.25%), sutural bones were observed at the frontomaxillary suture unilaterally. Two (0.6%) skulls depicted them on the right side (mean vertical and transverse diameters- 0.4 ± 0.1 mm and 6 ± 1.3 mm respectively) while the other two (0.6%) skulls presented them on the left side

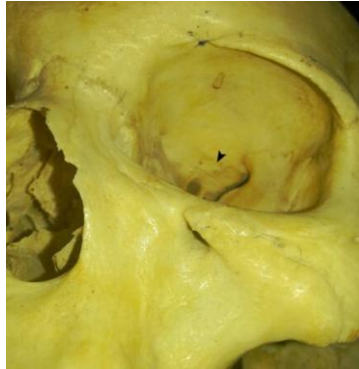

Fig. 7 Sutural bone at the junction of orbital plate of frontal bone and the lesser wing of sphenoid in the roof of left orbit (arrowhead)

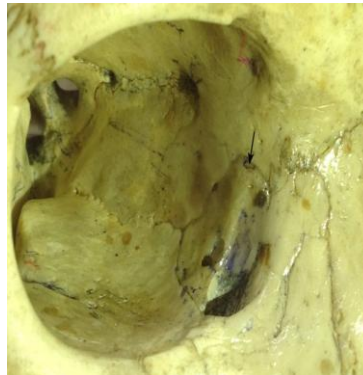


Fig. 8 Sutural bone at the frontolacrimal suture on the right side of facial skeleton (arrow)

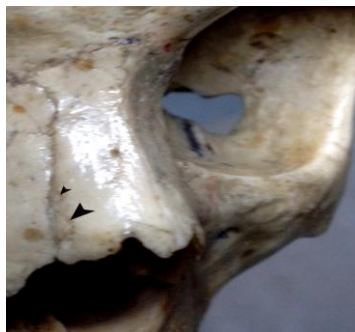

Fig. 9 Sutural bones on the face at the nasomaxillary suture on the right side of facial skeleton (arrowheads)

Locus 12: In eight skulls (2.5%), sutural bones were observed unilaterally at the frontomaxillo-lacrimal suture. Five (1.6%) skulls depicted them on the right side while the other two (0.6%) skulls presented them on the left side.

Locus 13: In four skulls (1.25%), sutural ossicles were noticed at the nasomaxillary suture unilaterally. It was seen in two

(0.6%) skulls on the right side. It was seen on the left side in two (0.6%) skulls (Fig. 9)

Locus 14: In six skulls (1.9%), it was seen at the maxillozygomatic suture bilaterally in four (1.25%) and unilaterally in the other two (0.6%) skulls.

Locus 15: In two skulls (0.6%), they were seen lateral to infra-orbital foramen unilaterally.

Table 1: Prevalence of sutural bones in the walls of the orbit and the facial skeleton along with their dimensions

n=320	Total number of sutural bones (%)	Bilateral (no.)	Unilateral (no.)		Dimensions of sutural bones(in mm)			
			Right side	Left side	Right side		Left side	
Locus					Vertical diameter	Transverse diameter	Vertical diameter	Transverse diameter
Lateral Wall								
1.Frontozygomatic suture	8(2.5%)	-	8	-	10±0.7	4±0.4		
2.Sphenozygomatic suture	16(5%)	12	2	2	10±0.5	13±0.7	3±0.4	9±1.5
3.Frontosphenoidal suture	4(1.25%)	-	4	-	35±5.5	50±6.7		
4.Sphenofrontozygomatic	12(3.75%)	8	2	2	10±0.4	7±0.3	8±0.4	6±1.5
Medial wall								
5.Frontoethmoidal suture	12(3.75%)	-	9	3	3±1.2	1±0.9	2±0.8	1±0.7
Floor								
6.Ethmoidomaxillary suture	8(2.5%)	-	6	2	30±3.2	15±1.5	27±4.5	13±1.4
Roof								
7.In the orbital plate of frontal bone	8(2.5%)	-	5	3	8±1.2	4±2.2	9±2.3	4±1.2
8.Junction of lesser wing of sphenoid and orbital plate of frontal bone	4(1.25%)	-	1	3	6±1.3	5±2.2	8±2.4	5±2.3
Face								
9. Frontolacrimal suture	2(0.6%)	-	2	-	0.5±0.1	3±0.9		
10. Maxillozygomaticolacrimal suture	4(1.25%)	-	3	1	7±3.5	21±5.1	5±1.3	16±2.8
11. Frontomaxillary suture	4(1.25%)	-	2	2	0.4±0.1	6±1.3	0.6±0.2	5±0.2
12. Frontmaxillolacrimal suture	8(2.5%)	-	5	3	2±0.7	5±0.9	2±0.3	6±0.5
13. Nasomaxillary suture	4(1.25%)	-	2	2	4±0.5	3±0.4	5±0.4	3±0.3
14. Maxillozygomatic suture	6(1.9%)	4	1	1	22±9	15±3	18±5	12±2
15. Lateral to infra-orbital foramen	2(0.6%)	-	1	1	0.4±0.1	0.6±0.1	0.5±0.2	0.4±0.2

Discussion

Orbit is a closed pyramidal space bounded by four bony walls. It contains eyeball and important neurovascular structures.

In the present study, orbital sutural bones were seen in 72 (22.5%) skulls which are more than those observed by Manjunath [2] in 25(15.34%) of the total 163 skulls. This could be due to greater sample size (320 skulls) in the present study.

To facilitate discussion, the present study has been highlighted under the following headings:

Location, size and shape

In the present study, highest number of SBs were observed in the lateral wall of the orbit (12.5%) followed by the facial skeleton (9.4%), medial wall (3.75%), roof (3.75%) and floor (2.5%), in that order. In the lateral wall, they were seen at the sphenofrontozygomatic, frontozygomatic, sphenozygomatic and frontosphenoidal sutures which is in conformity with the observations of another author (Manjunath, 2013) who observed them at similar loci but in lesser percentage (11.04%) than the present study, which could be due to the different group of population studied by him (South Indian population). In the present study, the most common location for the occurrence of sutural bones is sphenofrontozygomatic and frontoethmoidal (Fig. 4a, 4b, 5a, 5b, Table 1).

Also, accessory ossicles in the sphenozygomatic suture on the lateral wall have been reported by some other authors but their percentage of prevalence has not been reported (Bron *et al.*, 2013). In the medial wall of the orbit, sutural bones were observed in 3.75% skulls at the frontoethmoidal suture while 2.5% skulls presented sutural bones in its floor at the ethmoidomaxillary suture which has not been reported, to the best of our knowledge. In the present study, eight (2.5%) sutural ossicles have been seen in the orbital plate of frontal bone while four (1.25%) were appreciated at the junction of lesser wing of sphenoid and orbital plate of frontal bone in the roof of the orbit, amounting to a total of 3.75% which is similar to observations of another researcher (Manjunath, 2013) who observed them in 4.29% skulls. Some sutural ossicles have also been reported by an author (Ward, 1876) in the roof of orbit in the lesser wing of sphenoid and ethmosphenoidal suture which were not observed by authors of the current study.

In the present study, 30 sutural bones have been reported in the facial skeleton. The present study demonstrates myriad presentations of shapes varying from round, oval, oblong, triangular, quadrilateral and polygonal. Similar findings were also noted by another investigator (Chambellan, 1883). In the present study, the size of the sutural bones varies from $1\pm 0.9\text{mm}$ to $30\pm 3.2\text{mm}$ in the right orbit, the largest being seen in the frontosphenoidal suture and $1\pm 0.7\text{mm}$ to $27\pm 4.5\text{mm}$ in the left orbit. In the facial skeleton, the size ranged from $0.4\pm 0.1\text{mm}$ to $22\pm 9\text{mm}$ on the right side and 0.4 ± 0.3 to 18 ± 0.7 on the left side but according to a study by on 485 skulls, the size of sutural bones in the right orbit ranged from less than a millimeter to 10mm while in the left orbit from less than a millimeter to 5mm (Chambellan, 1883). This difference in size could be due to different races (Chambellan, 1883) as compared to the present study.

Laterality

Predominant occurrence of sutural bones on the right side, in the present study, is in accordance with findings of another author (Chambellan, 1883). The findings of the present study are in contradiction to observations of another author who observed it symmetrically on both sides of the skull (Bellary *et al.*, 2013). The most consistent factor influencing side differences is the slight retardation of ossification on the right side owing to richer innervation on that side, associated with cerebral hemisphere dominance which is also partly mediated by blood supply [Kjellgren, 1944, Togerson, 1951]. The presence of SBs in orbit and their correlation with CT scan has not been done earlier so the CT findings of the present study could not be compared.

Clinical/Surgical significance

This study highlights their importance because of the intimate relationship of orbital bones with paranasal sinuses and cranial fossae which are of clinical importance, as the intracranial disease may spread to orbit and the converse applies. These SBs can cause confusion in the examination of skull by simulating fractures in the X-rays and CT scan as seen in the present study. In cases of head injury it may be mistaken for a fractured fragment of the bony wall of the orbit or it may get dislodged due to impact of the injury and damage the intraocular soft tissue structures. The knowledge of sutural bones is necessary in patients who are candidates for orbital surgeries involving approach through its various walls.

Conclusions

The organization and perplexing relations of neurovascular structures in the orbit and facial skeleton makes it imperative that surgeons be knowledgeable about the sutural bones (non-metric variants). The maxillofacial, neurosurgical and orbital disorders warrant meticulous preoperative evaluation of walls of the orbit for recognition and detailed knowledge of morphologic variants of sutural bones of orbit, radiologically (on CT scan) for understanding its complex regional anatomy, as it can mislead the clinician by diagnosing false fractures of skull bones.

Disclosure of conflict of interest

None.

Acknowledgements

The authors express their heartfelt gratitude to all the residents doctors and technicians of the Department of Anatomy, Lady Hardinge Medical College and Associated Hospitals, New Delhi, India, for their unconditional support and cooperation throughout the study. The authors are also thankful to the authorities of Lady Hardinge Medical College, for their cooperation.

References

- Bellary SS, Steinberg A, Mirzayan N, Shirak M, Tubbs RS, Cohen-Gadol AA, Loukas M. Suturalbones: A review. *Clin. Anat* 2013; 26(8): 922–7. Doi:10.1002/ca.22262
- Bron AJ, Wolff E, Tripathi RC, Tripathi BJ. The Bony orbit and paranasal sinuses. In: Wolff's Anatomy of the Eye and the Orbit. 8th ed. London: Chapman & Hall; 1997. p. 1-28
- Chambellan V. Etude Anatomique et Anthropologique sur les os Wormiens. Inaugural Theses. Paris; 1883
- Kjellgren K. Studien über die Entwicklungen der Neuronen nach der Geburt, ihre Regeneration und die Asymmetrien ihrer Verteilung beim Menschen. *Acta Psychologica et Neurologica* 1944. Supplement 29
- Manjunath KY. Supernumerary bones in the walls of the bony orbit. *People's journal of scientific research*. 2013; 6(1):7-12
- Torgerson J. Asymmetry and skeletal Maturation. *Acta Radiologica* 1951; 36:521-3
- Ward FO. *Outlines of Human Osteology*. 3rd ed. London; 1876. p. 34
- Williams PL, Bannister LH, Berry MM, Collins P, Dyson M, Dussek JE, Ferguson MWJ. *Gray's Anatomy*. 38th ed. Edinburgh: Churchill Livingstone; 1995. p. 555, 605